Anatomy



Muscle Review

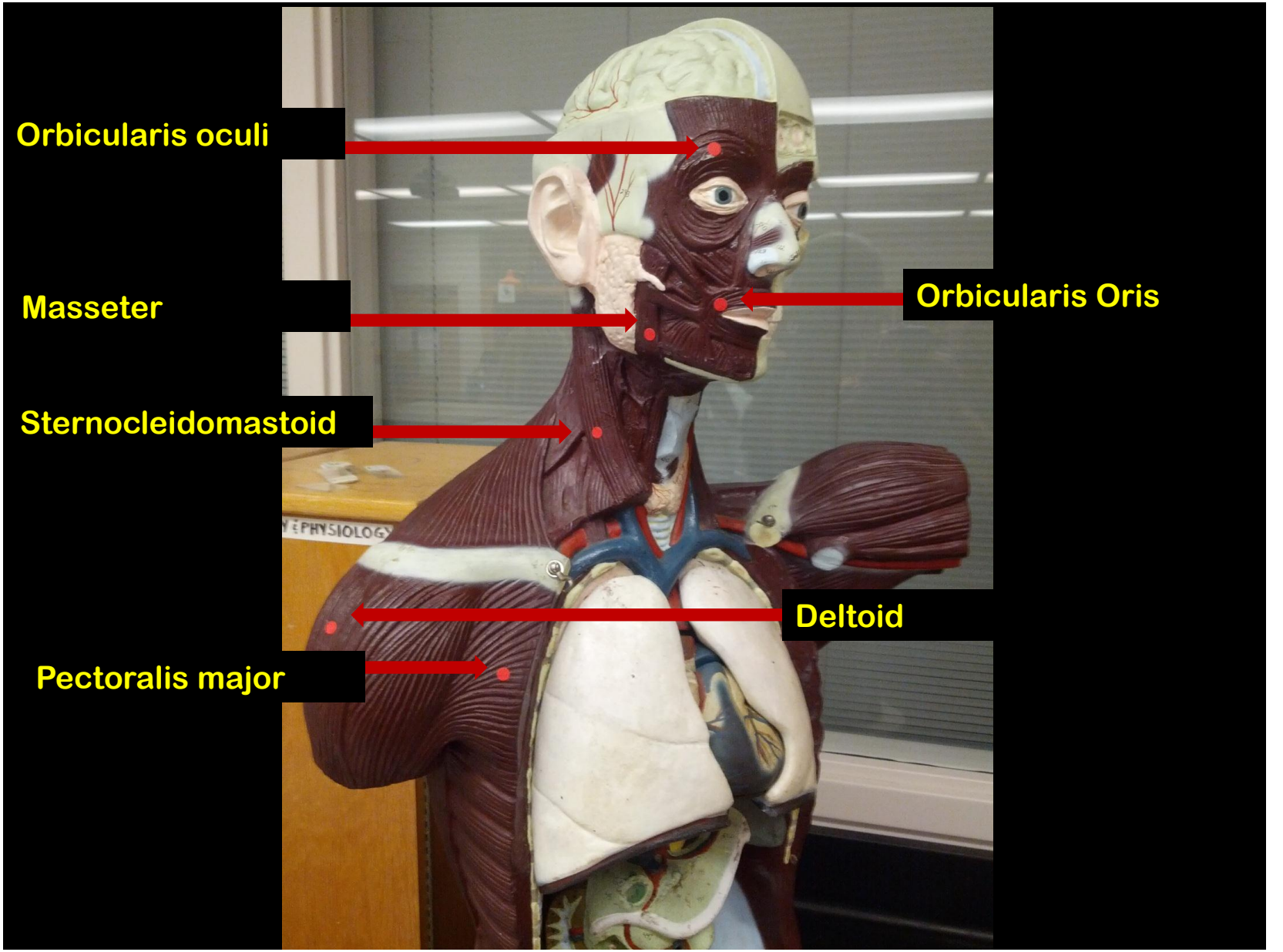
Orbicularis oculi
Masseter
Sternocleidomastoid
Pectoralis major
Orbicularis Oris
Deltoid


Sternocleidomastoid
Trapezius
Deltoid
Gluteus medius
Gluteus maximus

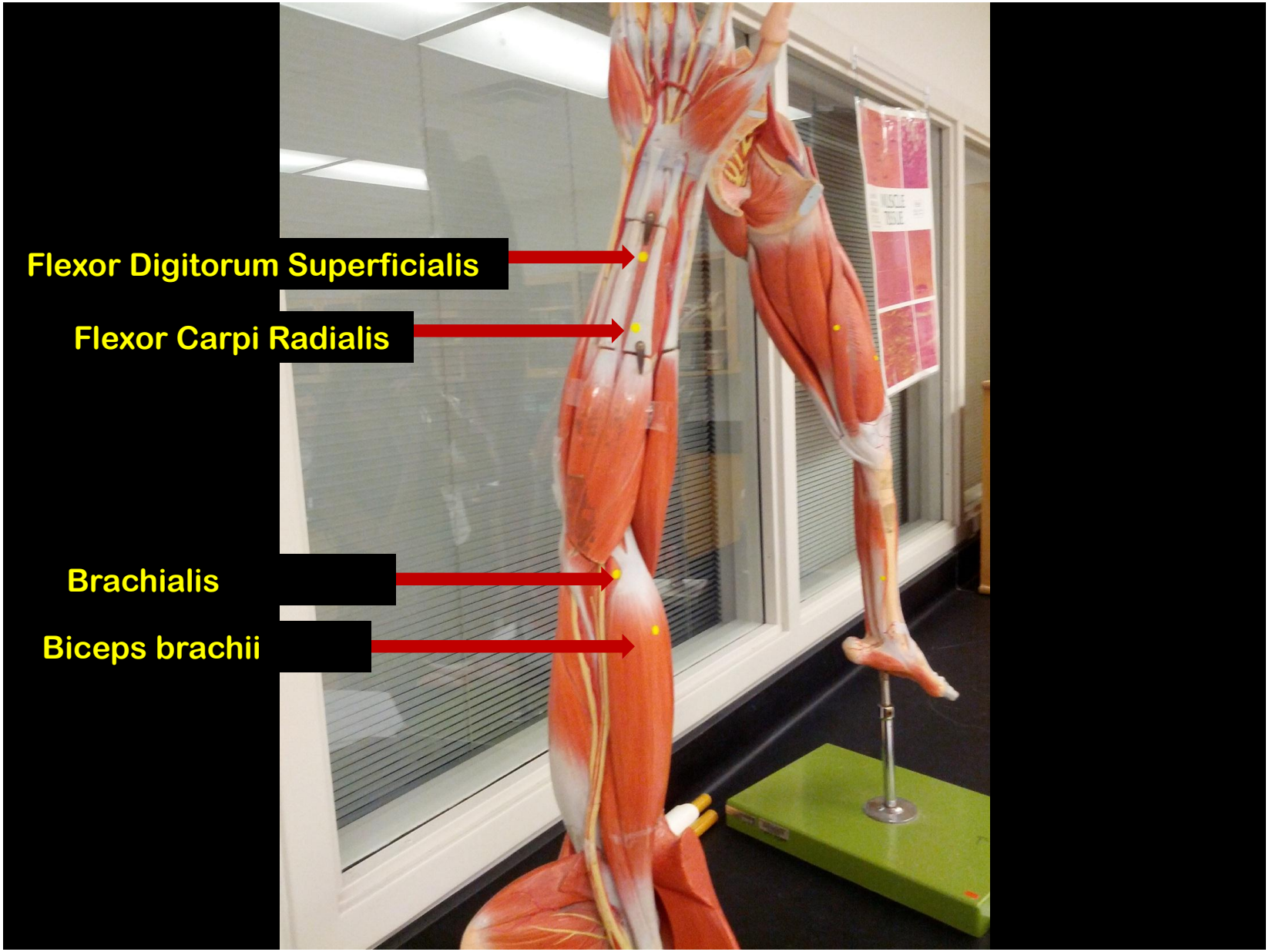
Flexor Digitorum Superficialis
Flexor Carpi Radialis
Brachialis
Biceps brachii

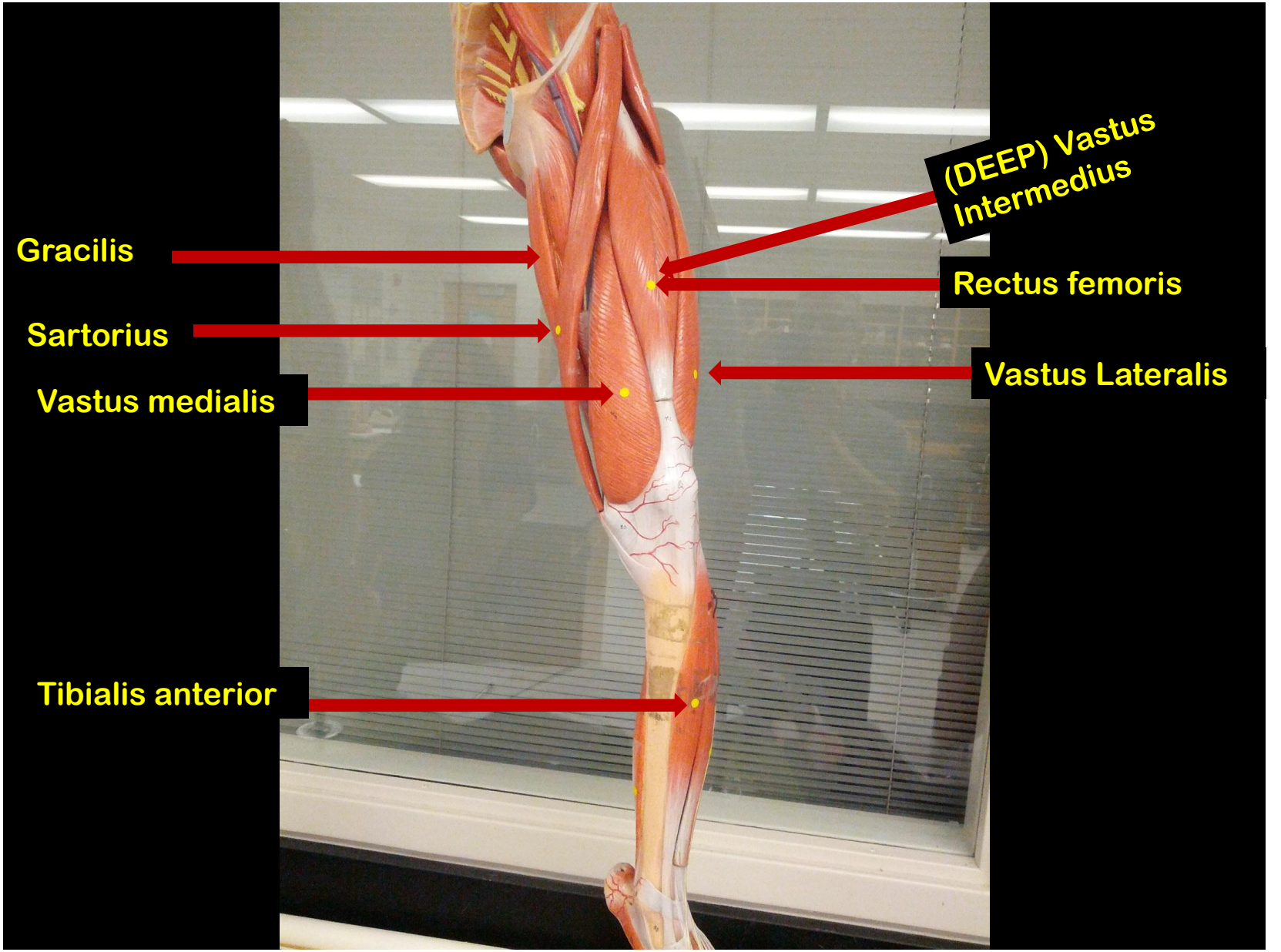
Gracilis
Sartorius
Vastus medialis
Tibialis anterior
(DEEP) Vastus Intermedius
Rectus femoris
Vastus Lateralis

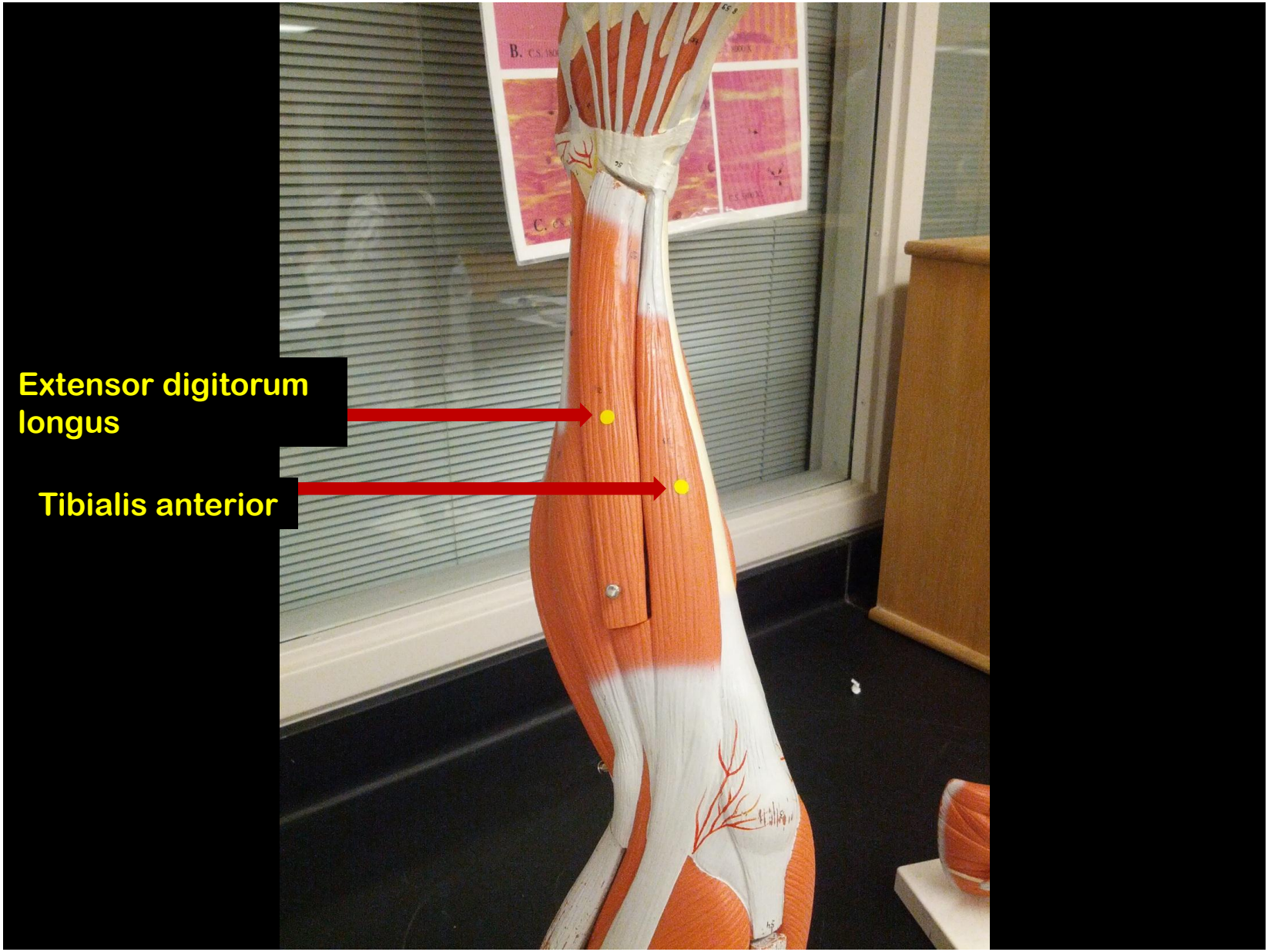
Extensor digitorum longus
Tibialis anterior

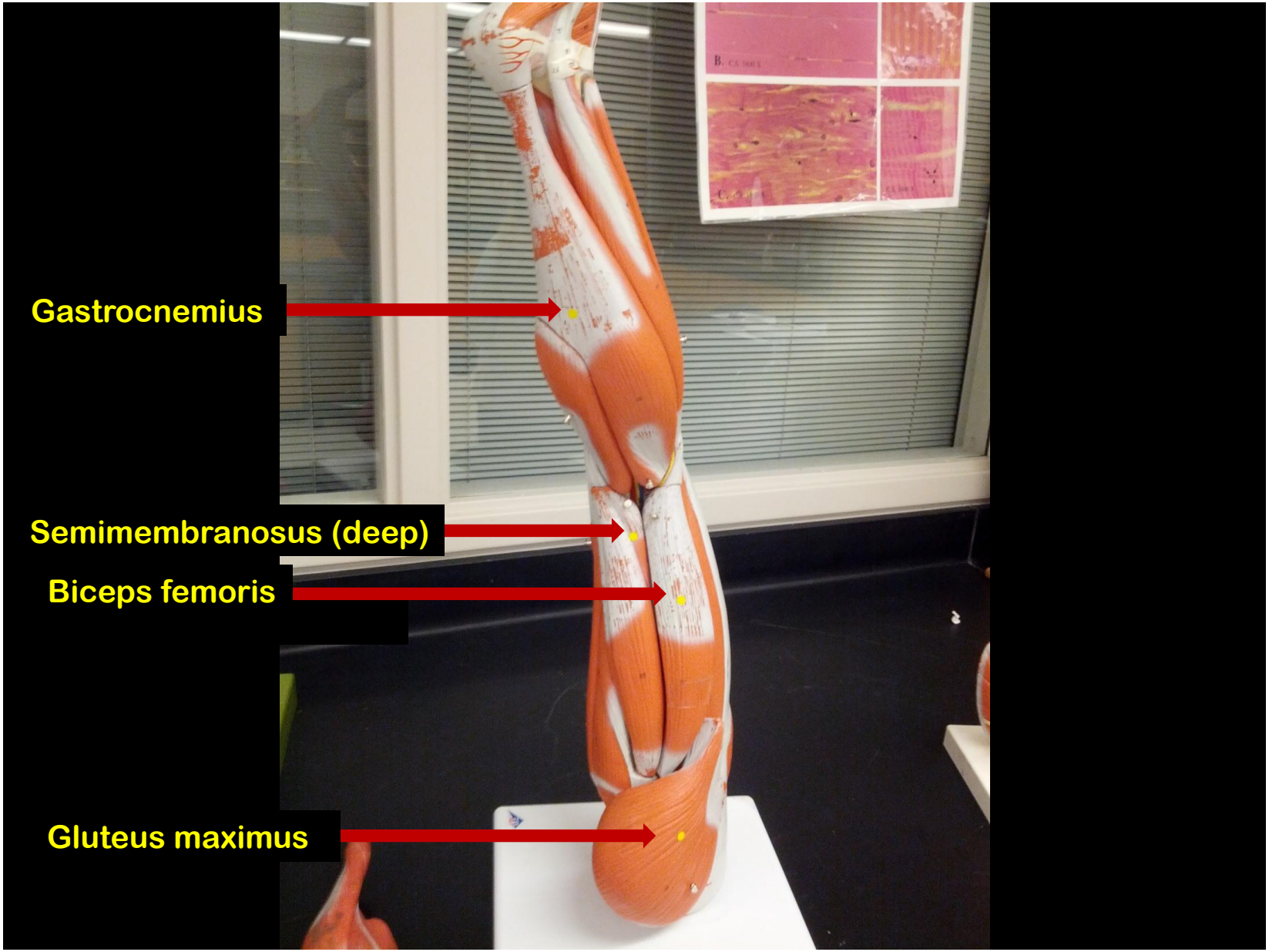
Gastrocnemius
Semimembranosus (deep)
Biceps femoris
Gluteus maximus

Origins and Insertions

Triceps brachii	Origin: Scapula & Humerus Insertion: Ulna
Biceps brachii	Origin: Scapula Insertion: Radius
Brachialis	Origin: Humerus Insertion: Ulna
Gastrocnemius	Origin: Femur Insertion: Calcaneus
Flexor digitorum longus	Origin: Tibia Insertion: Phalanges
Extensor digitorum longus	Origin: Fibula Insertion: Phalanges
Tibialis anterior	Origin: Tibia Insertion: Metatarsals

DAYTONA STATE COLLEGE

Questions

Prepared by

R. Hill – Anatomy Student

Edited by

D. Leonard - Learning Specialist

The Academic Support Center @ Daytona State College

http://www.daytonastate.edu/asc/ascsciencehandouts.html